



Newsletter

Summer 2011

01763 287744
office@tyrrellsequine.co.uk

Staff Changes and News in 2011



Firstly we would like to welcome Corrado Montoneri to Tyrrells. Italian vet Corrado has previously worked in Italy, America and more locally in Newmarket. His veterinary interests include lameness, orthopaedics and dentistry. On a personal level Corrado enjoys eventing, having competed at CCI*** for Italy, and on a more sedate note, playing his electric guitar!



We are also pleased to welcome Shirley to Tyrrells Equine Clinic as the new Practice Manager. Shirley brings a wealth of experience from a business environment, having been a Foodservice Marketing Manager working for a food manufacturer. When we can spare Shirley some free time, she can be found at her yard with her $\frac{3}{4}$ thoroughbred, Harry, and Diva her Italian Spinone. Shirley is also an active committee member of the Cambridge & District Riding Club, organising, helping and participating in events as well as acting as the club treasurer.



If you would like to discuss any matter regarding Tyrrells Equine please do feel free to contact Shirley on the office number.

We are also delighted to welcome back Catherine Seagroatt who has now returned from maternity leave. Catherine returns on a part time basis and is currently available on Mondays and Fridays.

Stephane Alkabes has now returned to Germany, hopefully Stephane will return occasionally for future surgeries here at Tyrrells. We would also like to congratulate Stephane on recently acquiring his board certificate in Equine Surgery. Well done Stephane!

Gold and Silver Schemes

We would like to take this opportunity to thank you all for your feedback and queries regarding the gold and silver health schemes proposed in the Autumn newsletter last year, we are hoping to initiate the schemes come the winter. Please feel free to continue giving us your feedback on this matter via email to office@tyrrellsequine.co.uk

No Visit Charges

Also remember we can reduce the costs of your veterinary visits. By ensuring that we see a minimum of 5 or more horses at a single yard no visit charge will be applied.

Equine Dentistry

Recently we had a case where a horse, who had previously been calm and relaxed whilst having its teeth rasped, had unexpectedly jumped forward during routine dentistry and the tooth rasp had caught in his mouth and into the muscles of the jaw alongside the larynx. The horse subsequently required hospitalisation and intra venous fluids to combat the acute blood loss that he suffered. Thankfully this patient made a full recovery.

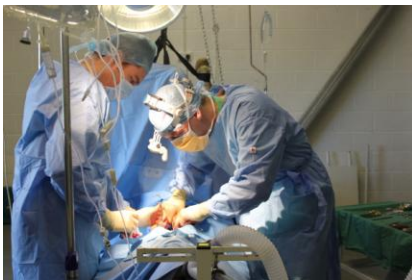

But what this incident does illustrate is the importance of sedation during a procedure where sharp instruments are in our horses mouths. Sedation can be delivered in two forms either via intra venous injection by the vet prior to rasping, or by an oral product called Sedalin which the owners can give prior to the vets visit. We would recommend the use of sedation for all cases, not only does it reduce the risk of cases as described above, but it also ...

- Makes it easier for the vet to perform a complete exam
- Reduces the risk of harm to the sensitive gums and oral mucosa
- Allows easier access to the back of the horses' mouth
- All in all reduces stress levels for horse

News Flash

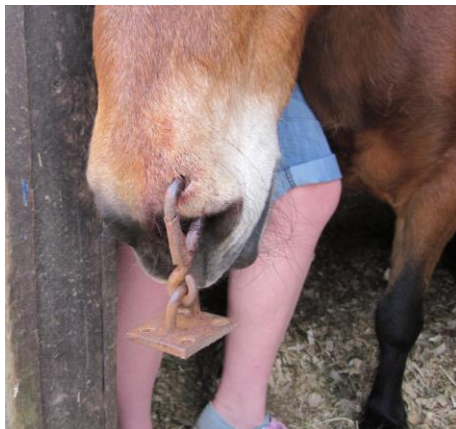
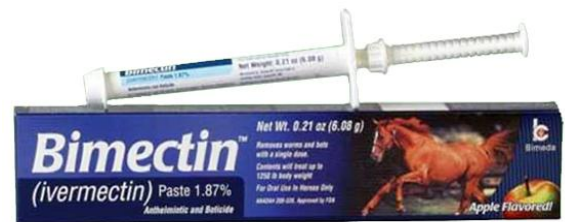Tyrrells Equine has recently supported a local community event in Kelshall, a casino night was held to help raise money for the village hall, by the end of the night we had helped to raise in excess of £400!



At the end of 2010 here at Tyrrells we performed our first colic surgery on a Shetland pony named Jade, after a successful surgery and some time spent convalescing, we are thoroughly pleased to announce that Jade is well on her way to recovery and is now enjoying her life to the full again.

Special Offers

Currently we have in stock in the office shop **BIMECTIN**, an ivermectin based wormer, which controls small and large redworms, for 10 weeks (the equivalent of Eqvalan), for the reduced price of £5.50. Please pop by for this and other offers.



Case of the month

Recently Jane was called out to see a rather inquisitive pony Noodle Doodle, who decided to do a bit of nasal self piercing!! Luckily Noodle Doodle was a sensible pony and with the help of a bit of sedation and a screwdriver he was quickly unattached from the wall and then the clasp unattached from Noodle! Thankfully he was only left with a small hole in his left nostril. However please be aware of the danger of these types of wall hooks within a stable, as it is not uncommon to be called to horses that have managed to hook themselves up, often with much more damage inflicted.